

CHOW JUDGES TRAINING SCHEME

ANATOMY AND THE CHOW

By Miss J. O. Joshua M.R.C.V.S

Printed by kind permission of the Midland Chow Chow Club and Miss J. O Joshua
(First published in the Midland Chow Chow Club Year Book 1948)

In view of the importance of knowledge of elementary anatomy of the skeleton and musculature of the dog in judging both soundness and breed point, it is surprising how little has been written on this subject. Breeders and exhibitors have had to acquire a smattering of information from various sources and as a result much misunderstanding is rife. Common examples are the description of stifles as hocks and vice versa, and the use of the term “narrow chest” when the fault is tied-in shoulders and so on.

It is proposed, therefore, to discuss in this article the elementary bony anatomy of the dog, with particular reference to the accepted breed standard. Whilst the author hopes to maintain an objective attitude to the features and faults under discussion, certain personal interpretations of various points are bound to creep in which will not meet with agreement universally. First it is necessary to consider the skeleton as a whole, and to realise that, no matter what the breed under discussion, the number of bones in the various parts of the body are invariable (with the exception of the tail). It is only by modification in shapes of individual bones and the angulation of the joints that differences of shape and size are manifest. Broadly speaking, the skeleton comprises the spinal column, which provides the supporting structure for the head, ribs and limbs, and is thus the most vital part of the body, (quite apart from its function of carrying and protecting within a bony canal the spinal cord), together with the previously mentioned attached structures, the head, ribs and limbs. The various parts of the body may now be considered in some detail with special reference to breed points.

1. THE HEAD

The head of the chow should be large in comparison with its body, and though much can be done by clever grooming of a profuse ruffle and head coat to give an impression of added size, no dog can have a really large head unless the bony structure is there. The first requirement in the standard is “skull , flat and broad”, which is perfectly clear and explicit. The bones of the skull should neither be domed from side to side, nor from front to back. The width of the skull is created by large plates of bone which project outwards beyond the cranium; the cranium being the bony cavity within the skull, which houses the brain, and from the back of which the spinal cord leaves the head. It should be noted that the cranium of the Chow is proportionate to the in other breeds and the breadth of the head does not denote a larger cranium and therefore brain.

The bones of the forehead – the frontal bones – gradually slope down to meet the nasal bones, which form the muzzle, and the depression or angle where the frontal and nasal bones meet is the “stop”. It is of interest to note that the standard states “with little stop”, i.e., the angle between forehead and muzzle should be gradual and slight. Compare this again quite specific requirement with many of the winners of today, and see how many fulfil it. Two types, which at present are doing much winning, have not only a pronounced stop, but in extreme cases the angle between the forehead and muzzle appears to slope backwards and downwards, giving the appearance of a “dish face”.

The muzzle comprises a number of bones, the principle ones being the nasal bones, and the bones of the upper and lower jaw, the superior and inferior maxillae. The nasal bones should be of moderate length and not tapering to a point at the tips; the bones of the jaw should be deep and powerful. This will fulfil the requirements of the Standard that says “muzzle – moderate in length, and broad from the eyes to the point”. Why is it that so many exhibitors interpret this point as “short and broad”, and even assert that the standard says “short”, is incomprehensible, and persistence on this interpretation will result in Chows with squashed up faces, quite alien to the original type.

The standard requires the teeth to be “strong and level”. The majority of Chows have excellent teeth, which are large and of good quality; it is unusual to see even Chows of ten years of age with badly tartared and missing teeth. Owing to the blunt end of the muzzle, the six small front teeth, the incisors, are set in a comparatively straight line, and are fairly widely spaced; this is in contrast to dogs with pointed muzzles, where the incisors are close together and set in an arc.

The expression “level”, as used in the standard, is taken to mean a level mouth, which in the dog denotes a scissor bite, i.e., the upper incisors fitting closely over and in front of the lower incisors. There should be no gap visible between upper and lower incisors when the mouth is closed, but equally, the teeth should not meet edge to edge.

2. THE SPINAL COLUMN

(A) **The Neck.** The cervical portion of the spine comprises the neck, and it is made up of seven vertebrae, the first two being specially modified in shape for special functions. The vertebrae immediately behind the skull is the atlas; this is a somewhat ring like bone which has large lateral projections called wings. The wings of the atlas in the Chow are large and can easily be felt behind the skull. The function of this bone is to allow nodding of the head.

The second specialised vertebra is the axis, a larger bone which has a large tooth like projection fitting into the ring of the atlas; this bone enables the head to be rotated from side to side. The remaining five cervical vertebrae are of standard type and comprise a solid body of bone – the centrum – and a canal encircled by bone, which is continuous along the spinal column as far as the sacrum, carrying the spinal cord. There are also projections of bone on all the vertebrae, which vary in shape and position according to the part of the spine in which the vertebra is situated. The standard again is quite clear in describing the neck, the first requirements being that it should be strong and full; these requirements will largely be met by the neck being clothed in good, strong muscle. The standard further states “set well on the shoulder and slightly arched”. This means that the neck should be sufficiently long to arch slightly as it rises from the shoulders, and in the writer’s view the ideal angle for the neck to be set on the shoulders is about 60°.

For the last twelve years an increasing proportion of Chows have had a tendency to be “bull-necked”, i.e., the neck is very short and pokes out of the shoulders almost horizontally. There is probably no single feature of the chow which can add to or detract from the general appearance and balance of the dog more than the set and arch of the neck, yet it is a feature seldom mentioned by judges or others in show critiques.

(b) The Dorsal or Thoracic Spine. This is the rib-bearing part of the spinal column and contains thirteen segments. The vertebrae form the roof of the chest, and each bears special articular (joint) surfaces to accommodate the heads of the ribs, which are likewise thirteen in number. There is little to be said about this portion of the spine except that it should be straight and strong, with no dip behind the shoulders. The chest will be considered separately later in this article.

(c) The Lumbar Region or Loin. This part of the spine comprises seven bones – the lumbar vertebrae. These follow the usual pattern, and have strong lateral projections of bone which extend outwards more or less horizontally.

The length of the individual bones will vary according to whether the dog is long or short-backed, and in a short-coupled, strong-backed dog like the Chow the couplings between the lumbar vertebrae should be firm and closely-knit, giving strength and rigidity to this part of the spine as opposed to the loose, suppler coupling in a long-backed breed.

Regarding the loins, the Standard uses the one word “powerful”, and this requirement cannot be met in a dog which the lumbar region is long, nor in one which “cuts up” or “cuts away” in loin; by this is meant a sharp tapering away of the calibre of the body, either from side to side behind the ribs, or from above to below. These permanent structural characteristics must always be differentiated from a “tucked-up” condition, which is usually met in animals temporarily out of condition, and is due to a decrease in the volume of the abdominal organs on account of absence of fat. On the other hand, some shaping over the loin is desirable, particularly in males, otherwise a shapeless sack like animal results; the shaping should not, however, be so marked as in the Pekinese, where a well-defined “waist” and light quarters are desired.

(d) The Sacrum. (roughly the area known as the croup). This forms the roof of the pelvis, and is in fact a solid wedge-shaped bone comprising three vertebrae fused together. At its widest, behind the last lumbar vertebrae, it tapers backwards towards the tail. In the Chow this end of the spine should again be short, broad and powerful.

(e) The Coccygeal Part or Tail. Contains a variable number of bones, usually some 20 – 23. In the Chow sweeps upwards and forwards immediately after its articulation with the sacrum, and is thus a part of the spinal column reflected upon itself.

3. THE CHEST

This is the portion of the body enclosed above by the thoracic spine, below by the sternum or breast-bone, and on either side by thirteen ribs. The thoracic spine has already been described. The sternum in the Chow ends anteriorly about level with the point of the shoulder; it should not project too far forward in the form of a “keel” (Dachshund) as this would set the fore legs too far back under the body, nor should it end abruptly posterior to the points of the shoulder, as this would give a weak and receding “front”, both of which are detrimental to general balance. The first nine ribs are attached at their lower limit to the sternum, each by a piece of cartilage, the next three are attached by a common cartilage, and the last rib – a short one- is not attached to the sternum at all, and is thus the “floating rib”

The standard says “Chest – broad and deep”. To meet these requirements the dorso-ventral (above to below) measurement of the chest has to be great, giving depth of chest, while breadth is achieved by the curving of the ribs well outwards from the spine before they curve inwards again to the sternum. This is “spring of ribs” and it is surprising how many Chows are found to fail in this respect on handling; many are slab-sided, and many are both slab-sided and shallow dorso-ventrally, resulting in a “shelly” body. A dog with a really good spring of ribs will have ribs which curve well outwards and slightly backwards as they leave the spine, enclosing a chest cavity having good capacity and if the depth of chest is also satisfactory, that dog can be said to have “good heart room”, or to be “well ribbed up”. It is this great depth of chest, correctly slung between stout fore-limbs, that enables a chow at once to be upstanding and yet not long in the leg.

The diameter of the chest is greater above than below, so that a cross-section through the chest would be heart-shaped rather than oval; an oval cross-section occurs in dogs that are narrow throughout, and have a truly “narrow front”. On the other hand “barrel” ribs are equally undesirable, particularly in the male. Barrel ribs are those which curve outwards so markedly that a cross-section through the chest would be roughly circular; they are invariably associated with a cloddy type of chow, and although their possessors are usually soundly constructed animals they again are not of the desired type. Bitches should have a somewhat greater degree of rounding of the ribs than dogs, but even so they should not approximate the cloddy bulldog type.

4. THE LIMBS

The forelegs. For a proper understanding of the anatomy of the limbs it is necessary to consider them section by section. The important point to note in connection with the fore limbs is that they are attached to the chest wall by muscles only, and have no joint at their union with the body.

(a) The Scapular or Shoulder Blade. This is roughly a triangular plate-like bone, and is known as the shoulder blade or blade bone. It is attached to the chest wall by powerful muscles. The correct application of the scapulae to the chest-wall is essential to obtain the correct type of fore-limb. The scapula slopes downwards and forward towards the shoulder joint, but it also tends to slope inwards and upwards towards the spine at its upper limit. The former angle determines the "slope of the shoulder" while the latter is described as being "laid back."

The Standard calls for a muscular and sloping shoulder; it has been suggested that "slightly sloping" would be more correct, and this is probably true in a breed where angulation is at a minimum. None the less, the shoulder blade should be applied to the chest at a slight angle, otherwise an upright shoulder results, which is undesirable on grounds of soundness in any breed, as it tends to give rise to a "pottering" front action. It may be of interest to note that one of the best-known winners of recent years has a very upright shoulder! Owing to the breadth of chest desirable in Chows, the shoulders cannot be described as well laid back; in a Terrier the upper edges of the shoulder blades nearly meet at the withers but in the chow there should be quite a distance between those edges. The lower end of the scapula forms a cup-like socket for the head of the humerus or bone of the upper arm, and this joint forms the "point of the shoulder" which, as previously mentioned, should be more or less in line with the anterior end of the sternum.

(b) The Humerus or bone of the upper arm – This is a so-called long bone, i.e., it has a marrow cavity. In the Chow the bone should be thick, and of great calibre. It runs downwards and backwards from the point of the shoulder to the elbow joint at an angle of approximately 60°. It also has muscles of attachment to the sternum and chest-wall, and if the muscles at its upper end, around the shoulder joint, are short, there will be a tendency for the points of the shoulders to be pulled in towards one another with the result that from that point the fore-legs will tend to splay outwards. This condition of being "tied in" at the shoulder is often mistaken for a narrow front, and it is this fault of conformation which was unfortunately becoming a frequent feature of a well known strain, immediately prior to the war. It was this fault that gave rise to the crude if descriptive phrase "two sticks out of one hole". It is usually associated with a weak and receding brisket. The muscle covering the shoulder blade and humerus should be strong and well developed, and it is this muscular character of the chow's shoulder which does much to add to the strength and squareness of the front.

(c) Radius and Ulna – Forearm. These are the bones of the forearm which run perpendicularly downwards from the elbow joint to the carpus of wrist joint. This is the part of the leg handled by the judge in assessing "bone". In the Chow the radius and ulna should be relatively short, of great calibre and dead straight. It is not commonly known that a number of Chows (and possibly other breeds) having "apparently" huge bone are, in fact, suffering from a form of rickets, and cannot be said to have "good bone". In such cases the rickets is due to vitamin "A" deficiency (Not D) and the result is a fore-shortening and curving of the bone with over production of bony tissue of poor quality. Such legs appear superficially straight, due to the covering of dense coat and "feathers", but on 'careful' handling a distinct bowing-out of the bone will be detected, together with the enlarged joints so typical of rickets. It will thus be realised that an appearance of colossal bone may not, in fact, be a good feature. In judging it is rarely possible to assess the actual bone; what is felt is a combination of bone, muscle and coat, which would be more accurately described as 'substance'. A dog will little leg hair often has bone of great calibre than its fellow with much

leg hair, but the optical illusion is mere deception, and it is probably true to say that the majority of judges assess bone visually rather than by touch, despite thorough handling.

(d) The Carpus or Wrist Joint. This joint is interposed between the lower end of the radius and the ulna and the upper extremities of the metacarpal bones. The joint comprises two rows of small bones, the names of the individual bones being of little importance here. The two rows of bones are held together by very short, tough interosseous ligaments, and a sprain of this ligament is common in puppies before the bones and joints are mature. Slackness of the interosseous and other ligaments associated with the carpus is a contributory cause of weak pasterns

(e) The Metacarpus or Pastern. Comprises five bones, the main one being considerably shorter than the remainder and carrying at its extremity the nail bearing digit, which is the dew claw. The Dew claw is a normal structure on the fore-limbs, and should, in the writer's view, not be removed. It does not detract from the appearance of the forelegs in Chows. The other four metacarpal bones extend downwards to articulate with the first phalanx of each of the four digits or toes. In the Chow these bones should be absolutely perpendicular to the ground and should not slope forwards as in breeds where a sloping pastern is desired; they should also be relatively short and of thick calibre, otherwise a tapering off towards the foot will be noticeable.

(f) The Digits or Toes. These are five in number, which includes the dew claw, but the foot proper contains four toes. Each digit comprises three bones, each of which is a phalanx, the terminal one being the claw. In the chow these phalanges should each be short, and should be moderately knuckled up to give the compact round foot which is desired. The term "cat foot" is not absolutely correct since the cat stands well back on the large centre pad, and has digits which it can stretch and spread, whereas the chow stands well forward on the toe pads, and off the centre pad to some extent, and the toes are tightly held together so that they cannot stretch and spread, as in the cat. The claws should be short, thick and meet the ground squarely so that they are constantly in wear, and are not obvious when the dog is standing normally.

5. THE PELVIS

The pelvis is somewhat complicated structure, the exact anatomy of which is not essential to an article of this type. Broadly speaking, it is a bony girdle, attached at its upper limit to the sacrum and providing the attachment for the hind limbs laterally. The pelvis includes three bones, the ilium, ischium and pubis. The ilium is a blade like bone, directed roughly upwards and forwards; one angle of the blade is united to the sacrum, and the other angle of the upper part of the is free, forming the angle of the haunch. This prominence can be clearly seen in dogs of the greyhound type, but in the chow the angle is rounded and covered by heavy muscle, and is therefore not easily seen or felt. The ischium and pubis virtually form the sides and floor of the pelvic cavity. In the Chow, a normal whelping breed, the pelvic inlet is of the natural and correct shape, roughly oval. The pelvis is roomy in the majority of chows, and it is comparatively rare to encounter dystocia (difficult birth) in this breed, due to over-size of the foetus, or smallness of the pelvic inlet.

6. THE HIND LIMBS

(a) The Femur or Thigh Bone. Is a long bone of heavy calibre which is attached to the pelvic girdle at the hip joint. This joint is a typical "cup and ball" joint, the acetabulum in the pelvis being the cup and the rounded head of the femur the ball. The femur runs downwards and forwards from the hip to the stifle joint, the angle varying according to the degree of angulation of the breed. In the Chow the femur drops almost perpendicularly to the stifle joint, and it cannot be too strongly emphasised that it is the absence of angulation from the hip joint to the toes that gives the chow its characteristic straight hind legs, and desired stilted

gait; it is too often assumed that it is the straight 'hock' which makes the hind leg what it is; but contrary, the angle of every part of the hind leg is vital to the correct chow quarters. The femur head should be surrounded by strong, well developed muscle of the thigh and buttock to meet the requirement in the standard for the hind legs to be muscular.

(b) The Tibia or Shin Bone, and Fibular. The tibia and fibula run downwards and backward from the stifle joint to the hock. Again the angle is slight, and the tibia drops very straight to the hock. The stifle joint is composed of femuro-tibial articulation, together with the patella, which rides on the anterior surface of the lower end of the femur. In the dog the patella is attached by two ligaments only, a superior and inferior, and has no lateral ligaments to assist in keeping it in place. Recurrent luxation of the patella, or "slipping knee-cap" is very common in the chow, and causes much lameness for which little or nothing can be done. In view of the lack of angulation at the stifle joint, it is very easy to see why the patella can slip from its position so readily. The tibia, again, should be a bone of heavy calibre, and comparatively short.

(c) The Hock Joint or Tarsus. Is a complicated joint involving two rows of bones of curious and assorted shapes. The joint is the equivalent of the human ankle and the point of hock would be the heel. A great deal is talked of "double hocks" in chows, a term used by all chowists to describe the hock which not only does not angulate backwards, as in other breeds but is so devoid of angle that it appears to flex in the forward direction. This description is not technically correct, since it is quite impossible for a joint of the anatomical make up of the hock to be so called double joint. It is again the complete absence of angulation which is so characteristic of the chow and the only modification anatomically is in the tuber calcis, the large upward projecting portion of bone which forms part of the os calcis, and is the point of the hock. In most breeds the tuber calcis is long and projects upwards, well clear and away from the back of the tibia, and over which the large tendons of the hind leg run; in the chow the tuber calcis is shorter, broader and blunter than in other breeds, and this, together with the absence of angulation at the hock, causes the bone to fit snugly in behind the tibia so that no point of the hock is detectable visually. In addition the profuse "feathering" of the back of the metatarsal region (below the hock) adds to the deception; almost all chows will show a degree of angulation, admittedly very slight, if the leg hair is removed by clipping, or is wet from a bath, sufficiently high to allow the whole joint to be seen.

(d) The metatarsal Region Downwards. From the hock downwards the anatomy is the same as in the fore-limbs, except for the fact that the fifth metatarsal bone does not normally bear a claw. Again, these bones should be short and of heavy calibre; if they are too long the dog cannot be said to have its hocks "well let down". The foot is similar to the forefoot, and the dog should stand well off the main pad giving the "on the toes stance" so much desired. In conclusion it may not be out of place to make a plea with breeders not to introduce exaggerations into a breed which should be a natural, soundly built dog. The essential feature of the chow is its sturdy, square sound on all fours, up-standing build and the moderate wording of the standard is a very sound basis on which to judge it.

The great danger in any breed is the interpretation of certain desirable point always in the superlative, and the introduction of words that are not in the standard. One example is the standard description of eyes as "dark and small" which now appears to be understood to mean the smallest possible, very deep set and black in colour; such interpretations, if persisted in, will lead to tragedy – deep set eyes are not mentioned in the standard yet it is always spoken of in discussing eyes. Also, while there is as yet no real scientific evidence that extremely dark eyes are not as efficient as, or are more liable to disease than, medium and lighter shades, there is some evidence accumulating which is making thoughtful breeders in several breeds wonder if insistence upon very dark eyes is wise.

On the other hand certain features which are described fully and clearly in the standard are never considered in judging, e.g., the neck, also the description of the shoulders and hindlegs as muscular, a state of affairs quite impossible in kennel-confined, unexercised dogs. The description of the back as short, straight and strong is often ignored – only recently a judge described an exhibit as perfectly balanced, which is not only undeniably not short in back, but has a distinct dip in it!

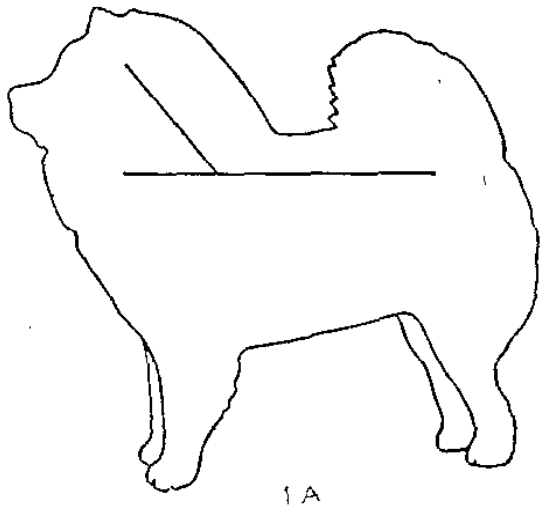
The requirement for powerful loins is again rarely mentioned, and one sees many dogs, which are narrow, light and weak in the loin, high up in the prize list. One could go on indefinitely considering the points which are over-emphasised in one decade and forgotten in the next, but the best judge will always be the one who goes for soundness first and foremost, and then considers general appearance next, leaving the minor points of description to decide the placing between exhibits of almost equal quality. Yet how rarely is this done!

Joan O. Joshua.

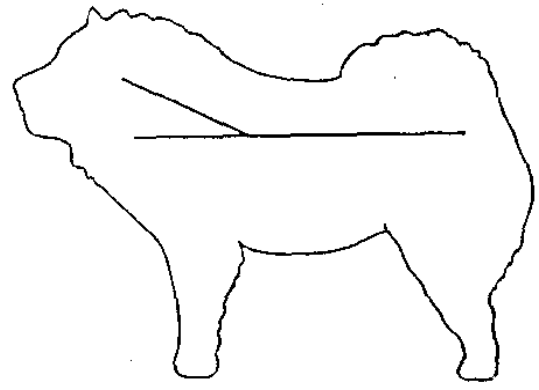
Key to diagrams

1. General Balance, with particular reference to set-on of head and neck.
 - A. Silhouette of Ch. Rochow Diadem, universally accepted as an exceptionally well balanced chow. Set on of neck approximately 60°
 - B. Bull-necked, poke-headed type, only appearing correctly balanced in ring by having head and neck pulled up hard. Set on of neck about 30°
2. Fronts
 - A. Correct, square front. Forelegs well spaced, dropping straight to ground, yet not out at elbow.
 - B. Narrow front, shoulder joints so placed that the points tend to approach one another, viz. “tied-in” shoulders. No space between forelegs, and legs splaying outwards from breast.
3. Ribs
 - A. Cross section of good, broad chest. Back strong and broad, ribs curving out strongly before coming to breast bone.
 - B. Narrow, slab-sided type. Back narrow and weak, ribs with little outward curve, giving a flat sided, weak chested type, with little heart room
4. Body shape and Loins
 - A. Short, straight, strong back; slight shaping of body towards loin.
 - B. Longer back, body tapering sharply upwards towards loin, ie., tucked-up and cut away in loin
 - C. Loin from above, showing slight shaping in short strong back
 - D. Weak loin, seen from above, narrow across the loin and narrow hindquarters.
5. Stop
 - A. Slight stop, and muzzle of moderate length as described in standard.
 - B. Marked stop and short muzzle as apparently liked by modern judges.

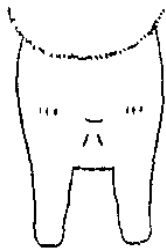Footnote 1987 The alteration to the standard to read “eyes fairly small” is interpreted to have the intention of encouraging judges not to select for smaller eyes, but regrettably this is still likely to occur.



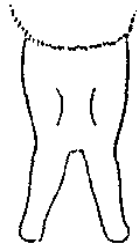1A



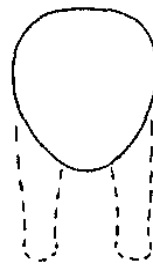1B



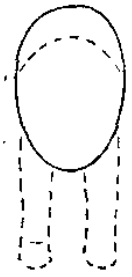
2A



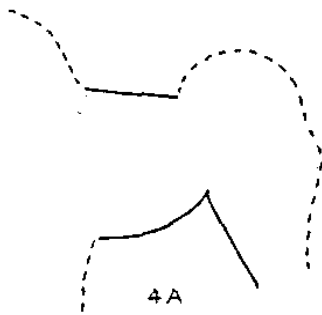
2B




3A



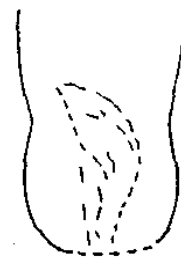3B



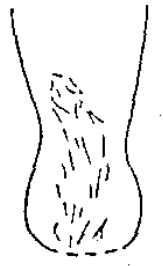4A



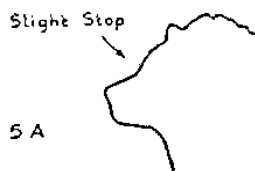4B



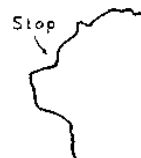4C



4D



5A



5B